



The effect of CO-Q10 on the testicular histological changes in rats induced by imatinib

L.I. Al-Allaf and H.A. Al-Ashoo

Department of Anatomy, College of Medicine, University of Mosul, Mosul, Iraq

Article information

Article history:

Received March 18, 2020

Accepted May 14, 2020

Available online November 5, 2020

Keywords:

Imatinib

Q10

Testes

Histology

Rat

Correspondence:

L.I. Al-Allaf

lumaallaf1971@yahoo.com

Abstract

The safety zone of imatinib, and specifically its relevancy to organ toxicity, has been discussed dialectically in current years. Oxidative stress may be one of the causes of imatinib-mediated toxicity. This study aimed to examine the possible role of co-enzyme Q10 in ameliorating the adverse effect of imatinib on the testicular histology of male albino rats -if it is present. Twenty-eight male Albino rats were used randomly assigned to 4 experimental groups: G1: 40-45 days aged rats (n=8) which were gavaged a dose of 200 mg/kg/day/30 days of imatinib mesylate. G2: age matched control rats which were administered with distilled water (n=4). G3: eight rats were received Q10, 50 mg/kg, alone, Q10-sorb capsule of 50 mg given with the same schedule. G4: eight rats were co-administered orally with 50 mg/kg of Q10+200 mg/kg of imatinib (once/day/30 days). Euthanizing of animals with ether 24 hours after the final dose was done. Testes of rats from each experimental group were obtained. The tissues processed and stained by routine histological method. Histological sections of testes of rats treated with 200 mg/Kg of imatinib revealed different testicular lesions compared to those of control group ($P<0.05$). Six (75%) of these sections revealed degenerated tubules, detached Sertoli cells, and apoptosis. These histological sections also showed thick tunica albuginea, seminiferous tubules with thick basement membrane, sometimes only a few of Sertoli cells were appeared in histological sections of imatinib treated rats. Mean Johnsen's scores in these sections was 5.1 ± 0.1 ($P<0.001$). Features of retained spermatid were also noticed in some sections. There was significant reduction in both seminiferous tubular diameter and the epithelial height of histological sections of group 2 ($P<0.001$) with mean of 140.2 ± 3.2 μm and 14.8 ± 1.1 μm respectively. Moreover, the number of Sertoli cells/ seminiferous tubule were significantly increased ($P<0.001$), with mean of 27.4 ± 0.2 and Leydig cell number is also significantly raised with mean of 7.5 ± 0.5 . In conclusion, treatment of peripubertal rats with imatinib induced several testicular alterations (including Sertoli cells) in comparison to control rats indicated that this drug is a gonadotoxic agent as it affects the quality and quantity of spermatogenesis. An ameliorating effect of co-enzyme Q10 co-administration on imatinib-induced testicular toxicity was concluded.

DOI: [10.33899/ijvs.2020.126587.1347](https://doi.org/10.33899/ijvs.2020.126587.1347), ©2021, College of Veterinary Medicine, University of Mosul.

This is an open access article under the CC BY 4.0 license (<http://creativecommons.org/licenses/by/4.0/>).

Introduction

Tyrosine kinase inhibitors (TKIs) are a relatively recent class of anticancer agents that target cellular pathways over expressed in special types of tumors (1). Imatinib represents

the first-line treatment for chronic myelogenous leukemia (CML) and gastrointestinal stromal tumor (GIST). Many of the novel anticancer agents have not enough specificity and selectivity and have a tendency to suppress multiple targets (2-4). Several researches have investigated the possible

mechanism of imatinib-causing organ toxicity. There is a report of the GIST patient or CML patient with male gynecomastia and testicular hydrocele after exposure to imatinib mesylate (5,6). Interestingly, imatinib also showed adverse toxic action on cultivated cardiomyocytes, mostly due to a generation of endoplasmic reticulum (ER) stress, leading to diminished translation, an arrest in protein synthesis and oxidative stress which may be one of the causes of imatinib-mediated toxicity (1). Over the last twenty years, there has been a developing concept that reactive oxygen species (ROS) production has a vital role in a wide spectrum of cellular processes. ROS are heterogeneously a group of molecules and free radicals as a derivative product from diatomic oxygen, with a non-specialized range of reactivity (7). In general, various patterns of pathways are contributed in the production of ROS, lipid peroxidation is thought to have a potent effect on the toxicity mechanism of several xenobiotics (8), and it is happened by an assistant effect of oxygen-free radicals, and it is believed to be a critical cause of destruction and injury of the cellular membranes and has been suggested to play as a contributor in the development of chemotherapy-induced tissue damage (9,10). Rodents models have been applied to discuss the cytotoxic effects of chemotherapeutic agents on tissues to assess current therapeutic agents to avoid its harmful effects (including their oxidative impact) (11,12). The cleaning of free radicals and prevention of the lipid peroxidation have been reported to become the key target activities for growing much-accomplishing protection protocols versus chemotherapy induced tissue damage (13,14). CoQ10 (ubiquinone) is the unique naturally-occurring lipid soluble benzo-quinone (vitamin like) compound that is endogenously synthesized (15). It is located in the hydrophobic interior of phospholipid double layer of virtually whole the cellular membranes. Meat, fish, nuts, and specific oils are types of the richest nutritional sources of CoQ10 (16). It has been illustrated that there is a protective action of CoQ10 in different models of oxidative and inflammatory tissue injury (17,18). CoQ10 significantly decrease cell death (18). The effect of CoQ10 supplementation on exercise producing muscle damage and oxidative stress has been reported (19). In addition, it has been suggested to ameliorate the ochratoxin induced tissue damages (12). Recently, CoQ10 is potentially acting against renal tissue damage and renal dysfunction caused by chemotherapeutic drug as Adriamycin (18).

This study aims to examine the possible role of co-enzyme Q10 in ameliorating the adverse effect of imatinib mesylate on the testicular histology of male albino rats.

Materials and methods

Twenty-eight male Albino rats purchased from Animal House of the College of Veterinary Medicine, University of Mosul, Mosul, Iraq were enrolled in this study. Animals

were housed under controlled normal environmental laboratory conditions and animal facility and were kept in an air-conditioned room with 12-hours light and dark cycles, where the temperature 22 ± 2 °C and relative humidity 65-70% were kept constant. They were local bred and put individually in Animal House plastic cages (England) measuring 47×34×18 cm lined with wood chips (20). Animals were let to acclimatize for a week before any experiment was performed (21), and provided with free access of water *ad libitum* and pelleted standardized food (commercial rodent chow) (22). All rats received humane care, and procedures involving animals and their care were conducted in conformity with international laws and policies and the studies on animals accepted. The experiments were performed during the light portion (23). Animals were randomly assigned into 4 groups. Group 1, eight male rats exposed to 200 mg/kg body weight (BW) of oral imatinib (Glivec®, STI 571; Novartis- purchased from Ibn-Sena Teaching Hospital, Mosul) once daily for 30 days using gavage with 24 gage needle -imatinib group (24). Group 2, four male rats with age and weight matched rats which received D.W once/day/30days -following the same protocol applied to imatinib group- control group. Group 3, eight male rats were received Q10 (50mg/kg BW) alone with the same schedule -once/day/30 days (25)- Q10 group. Group 4, eight male rats were co administrated orally with 50 mg/kg BW of Q10+200 mg/kg BW of imatinib (once/day/30 days). Q10+ imatinib group.

Each treated animal was monitored for unconcealed signs of toxicity for the next four hours, and mortality throughout the next 24 hours (23). Imatinib doses selected were intended to be in the range of those used in clinical treatment regimens (23) (400-800 mg/d or 340-590 mg/m² based on a weight of 70 kg) dose surface area adjusted to body-weight, $f \times \text{mg/kg} = \text{mg/m}^2$, where f is a constant equal to 6.0 in rats (26).

Euthanizing of rats with ether (20) 24 hr after the final dose. Laparotomy was done and testes were excised and fixed in Bouin's solution (27,28). The histological analysis was conducted after processes of fixation, dehydration, clearing, impregnation and embedding in paraffin. Then tissues were submitted to sectioning by using rotary microtome to get sections of 5-6µm thickness, and staining with Harris hematoxylin and eosin stain (H&E) (29) and periodic acid Schiff's reagent stain (PAS).

The evaluation was blinded to treatment and any data. Ten randomly selected histological testicular sections from each rat were analyzed qualitatively for any disorganization of cytoarchitecture of seminiferous tubules, the presence of vacuoles, gaps, abnormal cells in the seminiferous epithelium, sloughing, and degeneration of seminiferous epithelium with examination of the interstitial spaces (30).

On the other hand, histological sections were assessed quantitatively (via visopan Reichert, Austria) where the diameter of seminiferous tubules (STD), epithelial height of

seminiferous tubules (SEH), mean number of Sertoli cells /ST and leydig cell no./ 16xfiled (16) (31). In addition, Johnsen' scores were used to analyze the effect of drug on spermatogenesis (32). The photomicrograph was taken in Leica microscope with camera (Optika)attached using plan apochromatic objectives. Data Were presented as Mean±SE and were analyzed using excel program and the data were analyzed using Microsoft SPSS software (version 17). P-Value is considered as significant when it <0.05.

Results

The current study enrolled rats which remained alive throughout the experimental period. There is an evidence of decrease food intake, diminished physical activity, however there is no evidence of losing hair.

At necropsy, no obvious gross tissue abnormalities were noted in the testes of any animal. Sections of rats belonged to control group showed normal appearance of the seminiferous tubules (Figure 1).

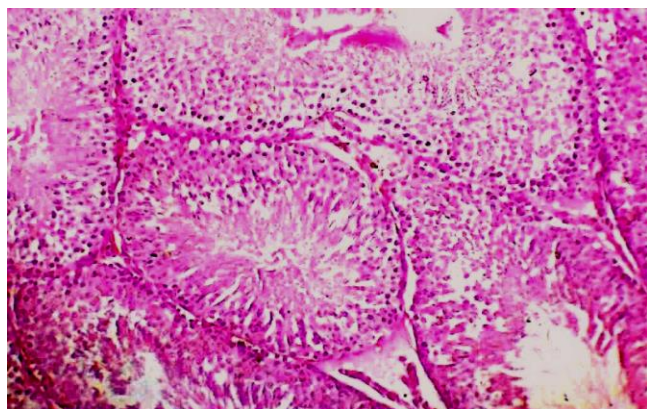


Figure 1: A photomicrograph of a testis of rat from control group with normal architecture of seminiferous tubule and interstitial tissue. H&E, ×250.

On the other hand, histological sections of rats treated with 200mg/Kg BW of imatinib (Group 1) revealed different testicular lesions compared to those of control group (Table 1) ($P < 0.05$). Six 6 (75%) of these sections revealed degenerated tubules, detached Sertoli cells (Figure 2), and apoptosis (Figure 3).

The histological sections showed thick tunica albuginea, seminiferous tubules with thick basement membrane. As shown in Figure 4, a few of Sertoli cells were appeared in some of these sections. Mean Johnsen's scores in these sections was 5.1 ± 0.1 (Figure 5) (Table1). Retained spermatid are present in some of these sections (Figure 6).

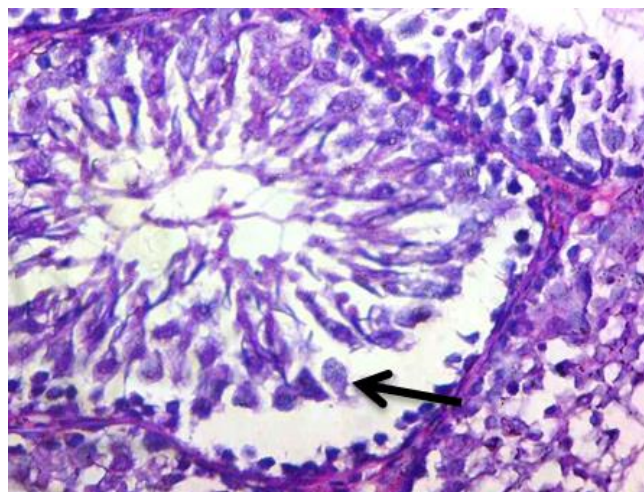


Figure 2: A Photomicrograph of a testis of a rat from group 1, showed detached sertoli cells (black arrow). (H&E×400).

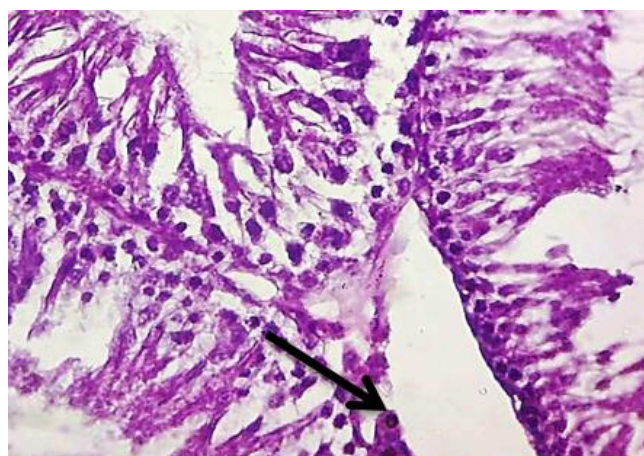


Figure 3: A photomicrograph of a testis of rat in group 1 showed dense apoptotic cells (arrow) with eosinophilic cytoplasm (H&E×250).

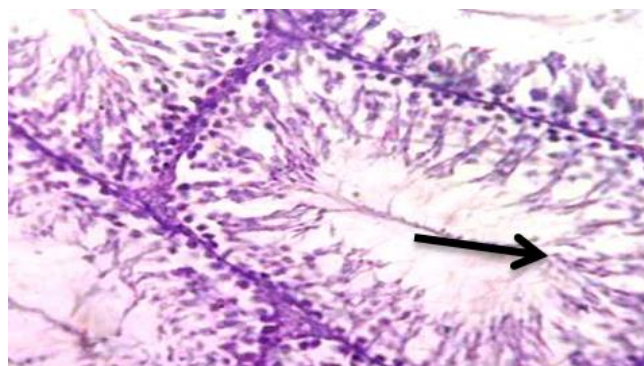


Figure 4: A photomicrograph of a testis of rat from group 1 showed depletion in Sertoli cells number (arrow) (PAS+H×600).

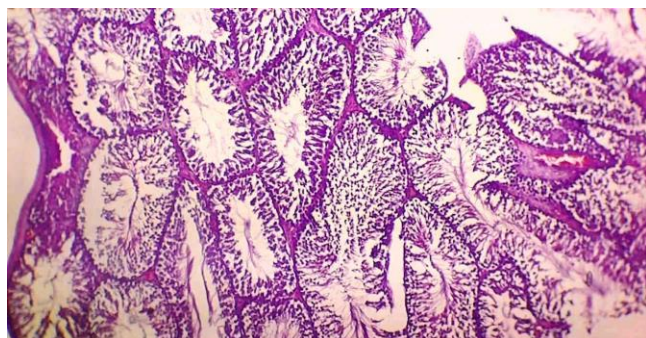


Figure 5: A photomicrograph of a testicular section of rat from group 1 showed decreased Johnsen's scores (H&E×250).

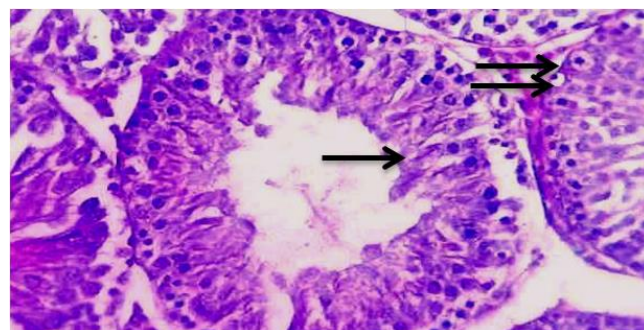


Figure 6: A photomicrograph of a testis obtained from rats treated with imatinib showed retained spermatids (arrow) and apoptotic cells (double arrow) (H&E×250).

Quantitative analysis

There was significant reduction in both seminiferous tubular diameter and the epithelial height of histological section from imatinib group ($P < 0.001$) with mean of $140.2 \pm 3.2 \mu\text{m}$ and $14.8 \pm 1.1 \mu\text{m}$ respectively. Moreover, the number of Sertoli cells/ seminiferous tubule was significantly increased ($P < 0.001$), with mean of 27.4 ± 0.2 and Leydig cell number was also significantly raised with mean of 7.5 ± 0.5 (Table 2).

The Effect of Q10 on testicular histology was analyzed in this study. The testicular histological sections of rats treated with co-enzyme Q10 alone (Group3) showed normal organized appearance of the seminiferous epithelium (Figure 7).

Animals submitted to this antioxidant treatment presented with best Johnsen's scores (with mean of 9.7 ± 0.5). On the other hand, quantitative analysis of these sections revealed that the mean of seminiferous tubular diameter of the rats received Q10 alone was $220 \pm 2.0 \mu\text{m}$ while that of the epithelial height of the tubules at this group was $73.0 \pm 1.3 \mu\text{m}$. The current study showed that histological sections obtained from animals which co-administrated with imatinib and Q10 (Group 4) appeared to improve germ cell line maturation and to inhibit the toxic effects on germ cell line observed in imatinib group. It was observed a better arrangement of seminiferous epithelium and appearance of tubules with luminal sperms (Figure 8).

Table 1: Frequency of the different histological observations and Johnsen's scores in the testicular tissues of group 1 and 2

Histological changes	Control N (%)	Imatinib N (%)	P-Value	
Disruption of normal cytoarchitecture	1(12.5%)	7(87.5%)	0.003	
Depletion of germ cell layer	1(12.5%)	7(87.5%)	0.001	
Detachment of germ cell layer from the basement membrane	0(0.0%)	7(87.5%)	0.0006	
Sloughing of germ cells toward the lumen	0(0.0%)	7(87.5%)	0.0006	
Vacuoles in the germinal layer	1(12.5%)	6(75%)	0.007	
Multinucleated giant cells	0(0.0%)	1(12.5%)	0.04	
Apoptosis	0(0.0%)	6(75%)	0.008	
Degenerated seminiferous tubules	0(0.0%)	6(75%)	0.001	
Thick basement membrane	0(0.0%)	6(75%)	0.002	
Sertoli cell abnormalities	Vacuolation	0(0.0%)	6(75%)	0.005
	Non-nucleated cell	0(0.0%)	5(62.5%)	0.03
	Detachment	0(0.0%)	6(75%)	0.005
	Sertoli only cell syndrome	0(0.0%)	1(12.5%)	0.9
Tunica albuginea	Thick Tunica albuginea	1(12.5%)	6(75%)	0.05
	Dilated blood vessels	0(0.0%)	3(37.5%)	0.04
	interstitial edema	0(0.0%)	7(87.5%)	0.0002
Interstitial space	inflammatory cells Infiltration	0(0.0%)	1(12.5%)	0.9
	Congested blood vessels	0(0.0%)	4(50.0%)	0.04
	Hemorrhage	0(0.0%)	3(37.5%)	0.16
Johnsen's Scores (1-10)	9.7 ± 0.5	5.1 ± 0.1	< 0.0001	

*P-value is considered as significant when < 0.05 . n=8.

Table 2: Effect of imatinib on some testicular morphometric parameters

Parameter	Control Group (Mean ± SD)	Imatinib Group (Mean ± SD)	P-Value
Diameter of the Seminiferous tubule (µm)	215.0±1.2	140.2±3.2	<0.001
Height of the epithelial layer(µm)	70.5±2.2	14.8±1.1	<0.001
Number of Sertoli cell /Seminiferous tubules	13.8±0.2	27.4±0.2	<0.001
Number of Leydig cell/Seminiferous tubules	5.1±0.6	7.5±0.5	<0.001

*P-value is considered as significant when <0.05. n=8.

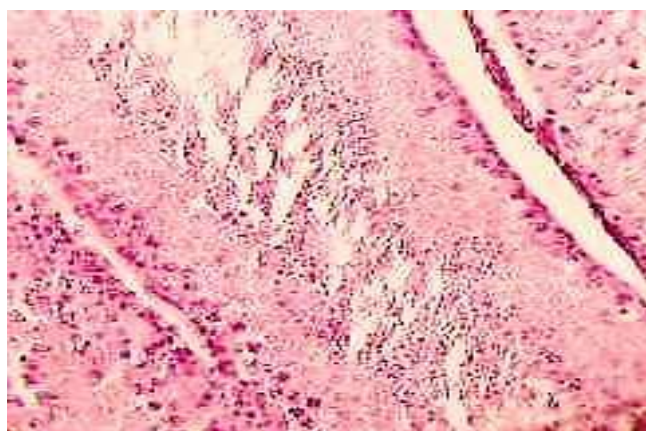


Figure 7: A photomicrograph of a testis of rat received Q10 alone showed normal appearance of the seminiferous tubule (H&E×250).

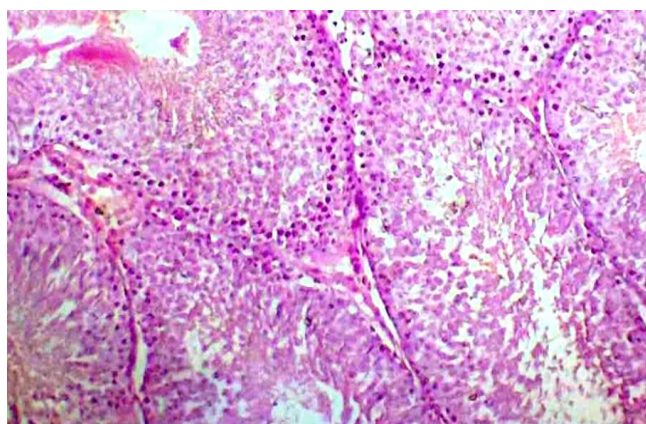


Figure 8: A photomicrograph of a testis of rat received Q10+imatinib with a better arrangement of seminiferous epithelium (H&E×250).

The seminiferous tubular diameter of those rats was significantly improved (mean 165.0±1.2µm). The mean epithelial height of the tubules was 40.3 ±0.8µm. Animals administered with co-enzyme Q10 and submitted to imatinib treatment exhibited better Johnsen's scores than rats administered with imatinib alone (Figure 9).

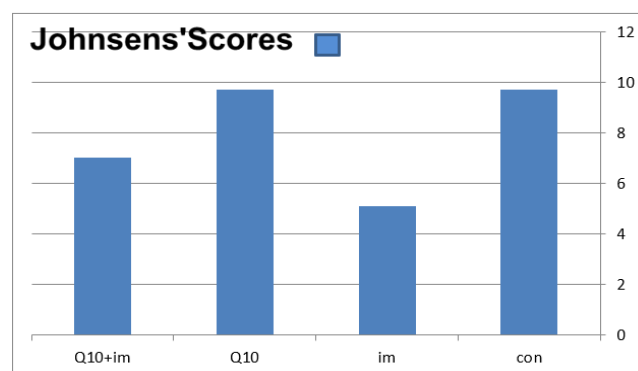


Figure 9: A histogram of the effect of Q10 on Johnsen's Scores of testicular histological sections. *Con; control, im; Imatinib, Q10; Q10 alone, Q10+IM; Q10+ Imatinib.

Discussion

Imatinib therapy is the first-line therapy for CML and GIST. In addition, other types of cancer are mostly to be treated by imatinib if activation of KIT or PDGFR is approved to be the cause from the molecular aspect (33). There is paucity of data on imatinib adverse influences on the testicular function particularly at peripubertal phase and the search in literatures revealed just one study by other authors where they demonstrated that imatinib strongly affects the quality of spermatogenesis in a group of peripubertal mice (30-33). Several testicular lesions were evident in the sections of rats which received imatinib particularly apoptosis and presence of degenerative changes of seminiferous tubules (p<0.05) respectively. These findings confirmed those of other researchers who reported that imatinib adversely influences the quality of spermatogenesis (34). In addition, this study revealed that the testicular alterations in the peripubertal period were regional, scattered. These findings are similar to those revealed by other authors (33).

The present study observed several changes of Sertoli cells as vacuolation, detachment from basement membrane, and nuclear abnormalities (P<0.05). These observations are in accordance with those of another study (20), which administered cisplatin to a group of peripubertal rats and reported that beside the profound impacts of the agent on germ cells, other critical changes were observed like Sertoli cell vacuolization, and their other changes observed in

testicular sections. Authors reported the persistence of some testicular changes and they suggested that chemotherapeutic agent may have affected this somatic cell without exposing it to cell death, as their number was not diminished (as noticed in this study), and they concluded that the effect on Sertoli cells leads to chronic impairment of spermatogenesis (20,35), however, another study did not mention changes in Sertoli cells after treatment with imatinib (29), that may be due to the administration of imatinib at adulthood and not at early phase as in this study.

Although imatinib has been affected the germ cell according to several reports, the effects of this agent on other testicular compartments are ill-defined. Favareto *et al.* (20) speculated that as spermatogenesis and steroidogenesis are not yet completely elucidated throughout peri-puberty, this may be a crucial phase of the reproductive development and subsequently more susceptible to changes induced by chemical agents (20). In general, chemotherapeutic agents are not regarded Sertoli cell toxicants. However, previous studies have suggested that etoposide, one of cytotoxic, beside the inducing damage to the germ cells, may also cause direct damages to Sertoli cells (36). The present study also provides a possible impact of imatinib on Sertoli cells. In fact, some Sertoli cell changes suggest that these cell damages are more obvious than those regarded as to be specifically secondary effects as an outcome from germ cell death. The Sertoli cells are vital in various key steps of spermatogenic lineage maturation and their resistance throughout the free radical attack may enhance the maintenance of seminiferous tubule integrity. On the other hand, the testicular interstitial components were comparable between group 1 and group 2, these findings were also consistent with those of another study (37), although morphological changes in the Leydig cell have not been clearly noticed under light microscopic examination. This present work revealed that Johnsen's Scores were decreased in imatinib administered rats in comparison to control ($P < 0.05$), these findings are in accordance with those of other contributors who used Johnsen's Scores for assessment of testicular functional impairment (32,38).

This study showed that histologic sections obtained from imatinib administered rats exhibited presence of cells with dense nuclei and eosinophilic cytoplasm using PAS+H stain. It has been reported that in the testis, apoptosis occurs in a spontaneous manner to keep homeostasis by diminishing damaged germ cells from the seminiferous epithelium (20) or can also be caused by several stimuli for examples: DNA damage, heat shock, growth factors inhibition and activation of apoptotic genes, caspase serial events, and oxidative stress (39). Another important lesion that should be concerned in this work is that sections of imatinib treated rats showed retention of spermatids. These findings are in accordance with those of other researchers who reported that retention of spermatids will result to defective spermiation (a process is regulated by Sertoli

cells), and damages to these cells can change spermiation and lead to spermatid retention (40).

Testicular histomorphometry analysis in this study revealed a significant reduction in tubular diameter and epithelial height as reported by other authors in rats and mice (30,31), but this alteration did not remain to adulthood. Researchers reported that imatinib adversely affects the quality and quantity of spermatogenesis. According to their findings and our previous observation, the spermatogenesis of rats under treatment with imatinib altered throughout the experimental period but returned to seminormal conditions after stoppage of treatment (27-31). These results indicate a time and dose dependent relationship. The abovementioned results are similar to those presented by Seshardi *et al.* (41).

Previous data that discussed the quantitative analysis of Sertoli and Leydig cells are scanty. The present study revealed that the number of Sertoli and Leydig cells is increased ($P < 0.001$). These findings are in accordance with those of Prasad *et al.* (30) who reported that hyperplasia of Leydig cells related with germ cell loss after imatinib treatment was also reported in mice (30). This is important because regulation of spermatogenesis is by Sertoli and Leydig cells (as mediators). However, a study which was done by authors showed a significant diminishing in number of Sertoli and Leydig (31), and that may be due to the factor of age of rats at time of exposure, the individual variations, and difference in the used methods of histomorphometry.

This work showed that animals administered with co-enzyme Q10 and submitted to imatinib treatment presented better scores than rats administered with imatinib alone. These observations are in accordance with those of other authors (25,42) who concluded that CoQ10 protects against sodium arsenate and doxorubicin associated testicular toxicities in rats via amelioration of oxidative stress (43), reduction of apoptosis and up-regulation of testicular P-glycoprotein. To our knowledge, this study is the first study that tried to discuss the effects of imatinib on the testes at peripuberty. Toxic impacts to the liver and kidneys may modify blood supply to the testes, and change detoxification processes and cause imatinib-related testicular toxicity in an indirect manner (44).

Conclusion

Treatment of peripubertal rats with imatinib induced several testicular alterations (including Sertoli cells) in comparison to controls indicating that this drug is a gonadotoxic agent as it affects the quality and quantity of spermatogenesis. An Ameliorating effect of co-enzyme Q10 co-administration on imatinib-induced testicular toxicity was concluded, confirming the role of oxidative stress in the mechanism of imatinib-associated testicular toxicity.

Acknowledgment

Thanks, are presented for the staff of the Consolatory Unit of Oncology in Ibn- Senna Teaching Hospital. We are grateful to the members of Animal house in College of Veterinary Medicine for their efforts in this study.

Conflict of interest

Authors declare that there is no any conflict of interest.

References

- Kerkela R, Grazette L, Yacobi R, Iliescu C, Patten R, Beahm C, Walters B, Shevtsov S, Pesant S, Clubb FJ, Rosenzweig A, Salomon RN, Van Etten RA, Alroy J, Durand JB, Force T. Cardiotoxicity of the cancer therapeutic agent imatinib mesylate. *Nat Med.* 2006;12(8):908-916. Doi: [10.1038/nm1446](https://doi.org/10.1038/nm1446)
- Ribeiro AL, Marcolino MS, Bittencourt HN, Barbosa MM, Nunes Mdo C, Xavier VF, Clementino NC. An evaluation of the cardiotoxicity of imatinib mesylate. *Leuk Res.* 2008;32(12):1809-1814. Doi: [10.1016/j.leukres.2008.03.020](https://doi.org/10.1016/j.leukres.2008.03.020)
- Wolf A, Couttet P, Dong M, Grenet O, Heronb M, Junker U, Laenglea U, Ledieua D, Marrer E, Nussler A, Persohna E, Pognana F, Rivièrec GJ, Robert Rotha DR, Trendelenburga CH, Tsao J, Danielle Romana D. Imatinib does not induce cardiotoxicity at clinically relevant concentrations in preclinical studies. *Leuk Res.* 2010;34(9):1180-1188. Doi: [10.1016/j.leukres.2010.01.004](https://doi.org/10.1016/j.leukres.2010.01.004)
- Whanopoulou E and Judson I. The safety profile of imatinib in CML and GIST: long-term considerations. *Arch Toxicol.* 2012;86:1-12. Doi: [10.1007/s00204-011-0729-7](https://doi.org/10.1007/s00204-011-0729-7)
- Gambacorti-Passerini C, Tornaghi L, Cavagnini F, Rossi P, Pecori-Giraldi F, Mariani L, Cambiaghi N, Pogliani E, Corneo G, Gnassi L. Gynaecomastia in men with chronic myeloid leukaemia after imatinib. *Lancet.* 2003;361(9373):1954-1956. Doi: [10.1016/S0140-6736\(03\)13554-4](https://doi.org/10.1016/S0140-6736(03)13554-4)
- Kim H, Chang HM, Ryu MH, Kim TW, Sohn HJ, Kim SE, Kang HJ, Park S, Lee JS, Kang YK. Concurrent male gynecomastia and testicular hydrocele after imatinib mesylate treatment of a gastrointestinal stromal tumor. *J Korean Med Sci.* 2005;20(3):512-515. Doi: [10.3346/jkms.2005.20.3.512](https://doi.org/10.3346/jkms.2005.20.3.512)
- Finkel T. Oxidant signals and oxidative stress. *Curr Opin Cell Biol.* 2003;15(2):247-254. Doi: [10.1016/s0955-0674\(03\)00002-4](https://doi.org/10.1016/s0955-0674(03)00002-4)
- Çeçen ŞŞ, Cengiz G, Söylemezoğlu T. The protective effects of n-acetylcysteine in paraquat induced toxicity. *J Fac Pharm Ankara* 2002;31(4):259-271. Doi: [10.1016/j.tox.2006.03.019](https://doi.org/10.1016/j.tox.2006.03.019)
- Vardi N, Parlakpinar H, Cetin A, Erdogan A, Cetin Ozturk I. Protective effect of β-carotene on methotrexate-induced oxidative liver damage. *Toxicol Pathol.* 2010;38(4):592-597. Doi: [10.1177/0192623310367806](https://doi.org/10.1177/0192623310367806)
- Sener G, Eks DE, Cetiner M, Ercan F, Yegen BC. β-glucan ameliorates methotrexate-induced oxidative organ injury via its antioxidant and immunomodulatory effects. *Euro J Pharmacol.* 2006;542(1-3):170-178. Doi: [10.1016/j.ejphar.2006.02.056](https://doi.org/10.1016/j.ejphar.2006.02.056)
- Turk G, Ates-s-ahin A, Sonmez M, Ceribaşı AO, Yüce A. Improvement of cisplatin-induced injuries to sperm quality, the oxidant-antioxidant system, and the histologic structure of the rat testis by ellagic acid. *Fertil Steril.* 2008;89 (5): 1474-1481. Doi: [10.1016/j.fertnstert.2007.04.059](https://doi.org/10.1016/j.fertnstert.2007.04.059)
- Sutken E, Aral A, Ozdemir F, Uslu S, Alatas O, Colak O. Protective role of melatonin and coenzyme Q10 in ochratoxin A toxicity in rat liver and kidney. *Int J Toxicol.* 2007;26(1):81-87. Doi: [10.1080/10915810601122893](https://doi.org/10.1080/10915810601122893)
- Silici S, Ekmekcioglu O, Eraslan G, Demirtas A. Antioxidative effect of royal jelly in cisplatin-induced testes damage. *Urol.* 2009;74:545-451. Doi: [10.1016/j](https://doi.org/10.1016/j)
- Motawi TMK, Sadik NAH, Refaat A. Cytoprotective effects of DL-alpha-lipoic acid or squalene on cyclophosphamide-induced oxidative injury: An experimental study on rat myocardium, testicles and urinary bladder. *Food Chem Toxicol.* 2010;48(8-9):2326-2336. Doi: [10.1016](https://doi.org/10.1016)
- Bentinger M, Tekle M, Dallner G. Coenzyme Q biosynthesis and functions. *Biochem Biophys Res Commun.* 2010;396(1):74-79. Doi: [10.1016/j.bbrc.2010.02.147](https://doi.org/10.1016/j.bbrc.2010.02.147)
- Pravst I, Zmitek K, Zmitek J. Coenzyme Q10 Contents in Foods and Fortification Strategie. *Crit Rev Food Sci Nut.* 2010;50(4):269-280. Doi: [10.1080/10408390902773037](https://doi.org/10.1080/10408390902773037)
- Schmidt M, Petry IB, Bohm D, Rimbach G, Niklowitz P, Menke T, Doring F. Effects of Coenzyme Q10 on TNF-alpha secretion in human and murine monocytic cell lines. *Biofact.* 2007;31(1):35-41. Doi: [10.1002/biof.5520310104](https://doi.org/10.1002/biof.5520310104)
- Aly NH. Reno - protective efficiency of coenzyme q10 on adriamycin-induced nephrotoxicity in rats. *J Appl Sci Res.* 2012;8(1):589-597.
- Kon M, Kimura F, Akimoto T, Tanabe K, Murase Y, Ikemune S, Kono I. Coenzyme Q10 supplementation Effect of on exercise-induced muscular injury of rats. *Exerc Immunol Rev.* 2007;13:76-88.
- Favareto APA, Fernandez CDB, Fossato da Silva DA, Anselmo-Franci JA, Kempinas WD. Persistent impairment of testicular histology and sperm motility in adult rats treated with cisplatin at peripuberty. *Basic Clin Pharmacol Toxicol.* 2011;109:85-96. Doi: [10.1111/j.1742-7843.2011.00688.x](https://doi.org/10.1111/j.1742-7843.2011.00688.x)
- Ilbey YO, Ozbek E, Cekmen M, Simsek A, Otunctemur A, Somay A. Protective effect of curcumin in cisplatin-induced oxidative injury in rat testis: mitogen-activated protein kinase and nuclear factor-kappa B signaling pathways. *Hum Reprod.* 2009;24(7):1717-1725. Doi: [10.1093/humrep/dep058](https://doi.org/10.1093/humrep/dep058). Epub 2009 Mar 11
- Urban JAD Souza. Toxic effects of 5-fluorouracil on sperm count in wistar rats. *Malaysian J Med Sci.* 2003;10(1):43-45.
- Mohan M, Bhandare S. Protective effect of *Solanum torvum* against testicular toxicity in male wistar rats. *Int J Pharm Pharmaceut Sci.* 2012;4(3):188-92.
- Al-Allaf LIK, Al-Ashoo HA. Analysis of the oxidative stress parameters in testicular, hepatic and renal tissues homogenates of albino rats after administration of imatinib at peripuberty. *Raf J Sci.* 2018;27(5):26-33.
- El-Sheikh AAK, Morsy MA, Mahmoud MM, Rifaai RA, Abdelrahman AM. Effect of Coenzyme-Q10 on Doxorubicin-Induced Nephrotoxicity in Rats. *Adva Pharmacol Sci.* 2012;981461:1-8. Doi: [10.1155/2012/981461](https://doi.org/10.1155/2012/981461)
- Bachmann K, Pardoe D, White D. Scaling basic toxicokinetic parameters from rat to man. *Environ Health Perspect.* 1996;104:400-407. Doi: [10.1289/ehp.96104400](https://doi.org/10.1289/ehp.96104400)
- Al-Allaf LIK, Al-Ashoo HA. The effects of imatinib on the testicular histology in male rats administered at peripubertal period. *J Arab Board Heal Special.* 2014;15(1):24-34.
- Afify M, Abd Elmaksoud MD, Mosa T, Elshaer M, Kotb N. Differential effects of amitriptyline treatment on testicular and liver functions in adult male rats. *N York Sci J.* 2010;3(3):1-3.
- Hasanin NA, Sayed NM, Ghoneim FM, and Al-Sherief SA. Histological and ultrastructure study of the testes of acrylamide exposed adult male albino rat and evaluation of the possible protective effect of vitamin e intake. *J Microsc Ultrastruct.* 2018;6(1):23-34. Doi: [10.4103/JMAU.JMAU_7_18](https://doi.org/10.4103/JMAU.JMAU_7_18)
- Prasad AM, Ramnarayan K, Bairy KL. Effect of imatinib on histological parameters in albino mice. *J Pharmaceut Sci Rev Res.* 2010;4(2):117-22. Doi: [10.4103/0253-7613.83107](https://doi.org/10.4103/0253-7613.83107)
- Yaghmaei P, Parivar K, Gharibi A, Nabiouni M. The biological effects of imatinib on male fertility of wistar rats. *Int J Fertil Steril.* 2009;3(3):135-142.
- Ceribasi AO, Turk G, Senmez M, Sakin F, Ateşşahin A. Toxic effect of cyclophosphamide on sperm morphology, testicular histology and

blood oxidant-antioxidant balance, and protective roles of lycopene and ellagic acid. Basic Clin Pharmacol Toxicol. 2010;107:730-736. Doi: [10.1111/j.1742-7843.2010.00571](https://doi.org/10.1111/j.1742-7843.2010.00571)

33. Heim C, Minniear K, Dann C. Imatinib has deleterious effects on differentiating spermatogonia while sparing spermatogonial stem cell self renewal. Reprod Toxicol. 2011;31(4):454-463. Doi: [10.1016/j.reprotox.2010.12.056](https://doi.org/10.1016/j.reprotox.2010.12.056)
34. Reddy VB, Sasikala P, Kartik A. Study on the effect of imatinib with special reference to alteration in histopathological parameters in male swiss albino mice. Inter J Advan Sci Tech Res. 2012;6:212-224.
35. Nurmio M, Kallio J, Toppari J, Jahnukainen K. Adult reproductive functions after early postnatal inhibition by imatinib of the two receptor tyrosine kinases, c-kit and PDGFR, in the rat testis. Reprod Toxicol. 2008;25(4):442-446. Doi: [10.1016/j.reprotox.2008.03.004](https://doi.org/10.1016/j.reprotox.2008.03.004)
36. Fiorini C, Tilloy-Ellul A, Chevalier S, Charuel C, Pointis G. Sertoli cell junctional proteins as early targets for different classes of reproductive toxicants. Reprod Toxicol. 2004;18:413-421. Doi: [10.1016/j.reprotox.2004.01.002](https://doi.org/10.1016/j.reprotox.2004.01.002)
37. Stumpp T, Sasso-Cerri E, Freymüller E, Miraglia S. Apoptosis and functional alterations in albino rats treated with etoposide during the prepubertal phase. Anat Rec. 2004;279(1):611-622. Doi: [10.1002/ar.a.20045](https://doi.org/10.1002/ar.a.20045)
38. Ramos SDP, Goessler KF, Ruiz RJ, Ferrari O, Polito M, Salles M. Exercise protects rat testis from cyclophosphamide-induced damage. Acta Scientiarum. Biol Sci Maringá 2013;35(1):105-113. Doi: [10.4025/actasciobiolsci.v35i1.12475](https://doi.org/10.4025/actasciobiolsci.v35i1.12475)
39. Kim JM, Ghosh SR, Weil AC, Zirkin B. Caspase-3 and caspase-activated deoxyribonuclease are associated with testicular germ cell apoptosis resulting from reduced intratesticular testosterone. Endocrinol. 2001;142:3809-16. Doi: [10.1210/endo.142.9.8375](https://doi.org/10.1210/endo.142.9.8375)
40. Brilhante O, Okada FK, Sasso-Cerri E, Stumpp T, Miraglia SM. Late morfofunctional alterations of the Sertoli cell caused by doxorubicin administered to prepubertal rats. Reprod Biol Endocrinol. 2012;10:79. Doi: [10.1186/1477-7827-10-79](https://doi.org/10.1186/1477-7827-10-79)
41. Seshadri T, Seymour JF, McArthur GA. Oligospermia in a patient receiving imatinib therapy for the hypereosinophilic syndrome. N Engl J Med. 2004;351:2134-2135. Doi: [10.1056/NEJM200411113512024](https://doi.org/10.1056/NEJM200411113512024)
42. Fouad AA, Al-Sultan AI, Yacoub MT. Coenzyme Q10 counteracts testicular injury induced by sodium arsenite in rats. Euro J Pharmacol. 2011;655(1-3):91-98. Doi: [10.1016/j](https://doi.org/10.1016/j)
43. Ali SM, Nawfal AJ, Al-Okaily BN. Protective effects of coenzyme Q10 against sodium fluoride- induced reproductive disorders in male rats. Iraqi J Vet Sci. 2019;33(1):143-149. Doi: [10.33899/ijvs.2019.125534.1056](https://doi.org/10.33899/ijvs.2019.125534.1056)
44. LIK Al-Allaf, Al-Ashoo H. Histological changes of the rat liver after administration of imatinib mesylate: An experimental study. Iraqi J Pharm. 2019;14(1):39-50. Doi: [10.33899/iph.2019.161193](https://doi.org/10.33899/iph.2019.161193)

تأثير الأنزيم المساعد ك ١٠ على نسيج الخصية في الجرذان بعد تجريعها بالايمانتب

لمى إبراهيم العلاف و حافظ على محمود العشو

فرع التشريح، كلية الطب، جامعة الموصل، الموصل، العراق

الخلاصة

إن الجانب الأيمن للايمانتب وخاصة علاقته بسمية الأعضاء قد تمت مناقشته بطريقة متناقضة في السنوات الحالية. إن الجهد التأكسدي قد يكون واحدا من أسباب حصول سمية الأعضاء عن طريق الايمانتب. هدفت الدراسة إلى بيان الدور المهم للإنزيم المساعد ك ١٠ في تخفيف التأثير العكسي للايمانتب على التركيب النسيجي للخصية في ذكور الجرذان المهفأة إن وجد. أجريت الدراسة على ذكور الجرذان المهفأة وتم تقسيم الحيوانات إلى أربع مجاميع، المجموعة الأولى شملت ثمانية جرذان بعمر ٤٠-٤٥ يوم حيث تم تجريعهم بجرعة ٢٠٠ ملغم/كغم/٣٠ يوم من الايمانتب ميسيليت. أما المجموعة الثانية وهي مجموعة سيطرة بنفس العمر حيث تم تجريعها بالماء المقطر وعددهم أربعة. المجموعة الثالثة شملت ثمانية جرذان تم تجريعها بالإنزيم المساعد ٥٠ ملغم/كغم، لوحده من كبسولة سورب من إنزيم المساعد وأعطيت بنفس الطريقة. أما المجموعة الرابعة فشملت أيضا ثمانية جرذان جرعو بالفم بـ ٥٠ ملغم/كغم من كبسولة سورب من إنزيم المساعد + ب ٢٠٠ ملغم/كغم/٣٠ من الايمانتب ميسيليت. تم إجراء القتل الرحيم للجرذان بالايثر بعد ٢٤ ساعة من آخر جرعة. تم اخذ الخصية من كل مجموعة حيث مررت وصبغت بالطريقة الروتينية النسيجية. إن الشرائح النسيجية للجرذان المعاملة بالايمانتب، ٢٠٠ ملغم/كغم وهي المجموعة الأولى، أظهرت أذى نسيجي للخصية بالمقارنة مع مجموعة السيطرة، بأقل من ٠,٠٥ حيث أظهرت ٧٥% من الشرائح النسيجية وجود تنكس في النيبات المنوية مع انفصال لخلايا سرتولي وكذلك موت ميرمج للخلايا. أظهرت هذه الشرائح النسيجية تنخن في الغلالة البيضاء وللغشاء القاعدي للنيبات الناقلة للمني. أظهرت بعض الشرائح النسيجية وجود أعداد قليلة من خلايا سرتولي في الجرذان المعاملة بالايمانتب. كان معدل معايير جونسين $0,1 \pm 0,1$ بأقل من ٠,٠٠١. لوحظت علامات احتباس النطف في بعض الشرائح. كما لوحظ قلة في قطر النيبات الناقلة للمني والارتفاع الطلاني في الشرائح النسيجية للجرذان المعاملة بالايمانتب بأقل من ٠,٠٠١ وبمعدل $3,2 \pm 1,4$ مايكرون لكل واحد من النيبات الناقلة للمني قد ازداد بشكل ملحوظ بأقل من ٠,٠٠١ بمعدل $0,2 \pm 27,4$ وعدد خلايا لايدك ارتفع بشكل ملحوظ بأقل من ٠,٠٠١ بمعدل $0,2 \pm 7,0$. استنتجت الدراسة أن معاملة جرذان في فترة ما حول البلوغ بالايمانتب أدى إلى بضع تحويرات في الخصية (من ضمنها خلايا سرتولي) بالمقارنة مع مجموعة السيطرة مما يؤكد أن الايمانتب هو عامل سام للخصية وأثر على كمية ونوع عملية تكوين النطف. إن هناك تأثير تخفيفي للأنزيم المساعد عند إعطائه مع الايمانتب.